

## Study of Lip Prints as an Aid to Forensic Methodology

Boddupally Ravi Kumar\*, Nishat Ahmed Sheikh\*\*

---

### Abstract

*Background:* Human identification is one of the most demanding subjects and is based on scientific principles, the object of which is to identify and register individuals for both civil and criminal purposes. *Aim and Objective:* To check whether there are any peculiar /common lip patterns among males and females and to establish lip prints as a tool for identification. *Study Design:* It's a cross sectional Prospective study. *Method:* It was conducted on the children who are studying in Sixth standard to Tenth standard in the Local schools at Narketpally. 170 subjects were selected irrespective of their caste, religion, dietary habits & socio-economic status. *Observation:* Among males, it was found that intersected pattern was most common in compartments 1, 3 and 4, while the least common pattern in lip compartments 1, 2, was Undetermined. On evaluation of the lip prints of the females, compartments 1, 2 exhibited intersected pattern predominantly. However, in compartment 3 and 4, branched pattern was commonest. *Conclusion:* Lip prints are useful in personal identification and they differ from person to person even not similar in uniovular twins. Study showed that cellophane tape and lipstick can be easily used to retrieve lip prints. Lip print analysis is a process that can provides both qualitative and quantitative results.

**Keywords:** Forensic Identification; Lip Prints; Cheiloscopy.

---

### Introduction

Identity is a set of physical, functional or psychic, normal or pathological characteristics which define an individual. Human identification is one of the most demanding subjects and is based on scientific principles, the object of which is to identify and register individuals for both civil and criminal purposes [1].

In India, as well as all over the world today, crimes of diverse nature are on the rise. Both educated elite of the society and criminals are using sophisticated techniques while committing their crimes, to put the

forensic, police, and the public off the scene. Hence, the role of crime detectives has become tough than ever in this sophisticated modern world. As crime scene investigation procedures are becoming more systematic and scientific, criminals are coming up with novel techniques to beat them. Post-mortem reports and finger-prints of late, the DNA fingerprinting methods are being used to take out convincing evidence in a court of law. Forensic Pathologist plays a vital role in the identification of human remains [2-3].

The wrinkles and grooves on the labial mucosa (called sulci-labiorum) form a characteristic pattern called "lip prints," the study of which is referred to as Cheiloscopy [4-9]. Cheiloscopy is a new and less recognized forensic investigation technique that deals with the identification of humans based on lip prints.

The significance of Cheiloscopy is linked to the fact that lip prints are inherent, once developed at the 6th month of intrauterine life they are permanent, unalterable even after death, and unique to each person except for monozygotic twins. It has also been confirmed that lip prints recover after undergoing

---

**Authors Affiliation:** \*Asst. Professor of Forensic Medicine, Kamineni Institute of Medical Sciences, Narketpally, District Nalgonda, State Telangana. \*\*Professor of Forensic Medicine, People's college of Medical sciences & Research Centre, Bhopal.

**Reprints Requests:** Nishat Ahmed Sheikh, Professor, Department of Forensic Medicine, People's college of Medical sciences & Research Centre, People's University.  
E-mail: drnishatsheikh@gmail.com

alterations such as inflammation, trauma, and diseases like herpes and that the disposition and form of the furrows does not vary with environmental factors [10]. However, major trauma to lips may lead to pathosis, scarring and the surgical treatment given for lip rectification may alter the shape and size of the lips, thereby altering the pattern and morphology of grooves [11].

Cheiloscopy can be used as an invaluable tool in individual identification. There have been instances where "Cheiloscopy" has landed criminals behind bars, substantiating its acceptance in the court of law. Cheiloscopy can open new horizons in individual identification, be it crime scene or mass disaster. The present study was aimed to study the lip prints of different individuals in different parts of the lip and find out the incidence of any particular pattern in the given age group in relation to specific gender.

#### *Historical Perspectives*

R. Fischer was the first to describe it in 1902[12]. Use of lip prints in personal identification and criminalization was first recommended in France by Edmond Locard [13]. In 1950, Synder was the first person who suggested the idea of using lip print for identification. LeMoynes Snyder in his book Homicide Investigation, written as early as 1950, mentions the possible use of lip prints in the identification of individuals [14].

In the period 1968-1971, two Japanese scientists, Y. Tsuchihashi and T. Suzuki [15] examined 1364 persons at the Department of Forensic Odontology at Tokyo University. Based on this research, it was established that the arrangement of lines on the red part of human lips is individual and unique for each human being. This statement led to the conclusion that there is a possibility of using the arrangement of furrows (on a trace, in a linear form) on lips for the identification of a person. In Poland, the interest in lip prints started in 1966 when a lip print was revealed on window glass at the scene of a burglary [16].

#### *Classification by Suzuki and Tsuchihashi 1970 [15].*

Type I: Clear-cut vertical grooves that run across the entire lips.

Type I': Similar to Type I, but do not cover the entire lip.

Type II: Branched grooves (branching Y-shaped pattern).

Type III: Criss-cross pattern.

Type IV: Reticular, typical checkered pattern, fence like.

Type V: Undetermined, grooves do not fall into any of the types and cannot be differentiated morphologically

### **Material and Method**

Present study is a cross sectional prospective study, it was carried by the department of Forensic Medicine of Kamineni Institute of Medical Sciences Narketpally, on the children who are studying in Sixth standard to Tenth standard in the Local Government schools at Narketpally. 170 subjects were selected irrespective of their caste, religion, dietary habits and socio-economic status. Sufficient permissions and consents were procured before the study of the children is taken and clearance from the Institutional Ethical committee is obtained in advance. Investigators were trained for recording and analyzing lip prints. Calibration was done by recording lip prints of 10 students initially successively. Each student was examined twice and the results were compared, to know the diagnostic variability agreement.

Materials used: Dark shaded lip stick, Ear buds, Cellophane tape, White paper (Proforma for recording lip prints), Scissors, Magnifying lens and sanitary tissues (to wipe the lip stick).

Technique: The subjects were made to sit comfortably in an erect position. Lips of all the subjects were cleaned and wiped dry with tissue paper before the procedure. Dark colored lipstick was applied with a single stroke evenly on the lips. The subjects were asked to rub both the lips to evenly spread the applied lipstick. A neat strip of transparent cellophane about 20 cm was cut and the glued portion of cellophane tape strip was placed over the lipstick. The lip impression was made in the normal rest position of the lips by dabbing in the center first and then pressing it uniformly toward the corner of the lips. The subjects were asked to relax and then the cellophane strip was removed from the lips in a single stroke and then stuck to a white paper for permanent record purpose. The lip print procured was examined using a magnifying lens to confirm whether the print has been properly reproduced. These prints were examined using magnifying glass, classified, and analyzed. While studying the various types of lip prints, each individual lips were divided into four equal compartments, i.e., two compartments on each lip, and were allotted the digits 1 to 4 in a clock-wise sequence starting from the subjects upper right.

*Statistical Analysis*

The collected data were analyzed using SPSS version 18 (SPSS Inc., Chicago)

*Inclusion Criteria*

Subjects willing to participate in the study.  
Subjects free from any active or passive lesions on their lips.

*Exclusion Criteria*

Gross deformities of lips like cleft lip, ulcers, and traumatic injuries on lips.  
Known allergy to the lip stick used.

*Observation*

Total 170 children were included in the study, comprising in various age groups starting from 11 years to 16 years who are school going children. Girls 88 and Boys were 82 among them.

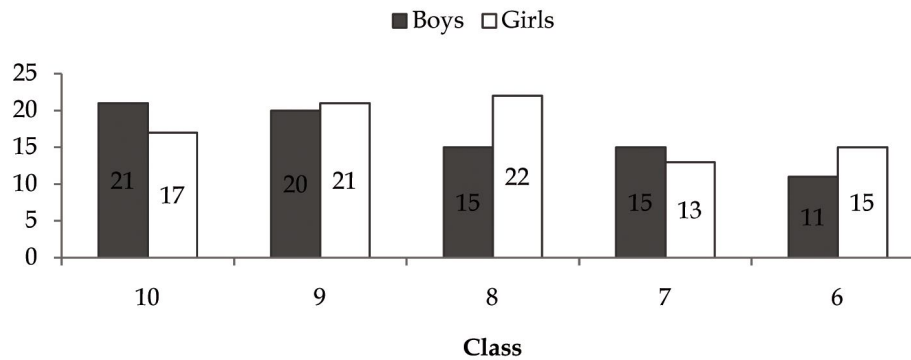


Fig. 1: Class wise Strength of Students

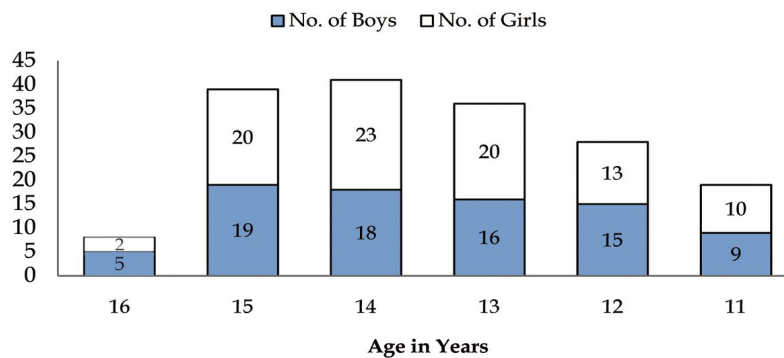


Fig. 2: Age and Sex Distribution of the Students

Table 1: Lip Print pattern in Boys and Girls

Lip Print	Males	Females
<b>Pattern</b>	(n=82x4=328)	(n=88x4=352)
Vertical	47 (14.32%)	67 (19.03%)
Branched	48 (14.63%)	98 (27.84%)
Intersected	114 (34.75%)	109 (30.96%)
Reticular	38 (11.58%)	32 (9.09%)
Undetermined	31 (9.45%)	27 (7.67%)
Poor quality	50 (15.24%)	19 (5.39%)

**Table 2:** Lip print patterns in each lip compartment of Males and females

Lip Compartment	Lip Print Pattern	Males (n=82x4=328)	Females (n=88x4=352)
I	Vertical	23 (28.04%)	19(21.59%)
	Branched	10 (12.19%)	18 (20.45%)
	Intersected	23 (28.04%)	22(25.0%)
	Reticular	6 (7.31%)	2 (2.27%)
	Undetermined	4(4.87%)	6 (6.81%)
	Poor Quality	16 (19.51%)	14 (15.90%)
II	Vertical	9 (10.97%)	16 (18.18%)
	Branched	24(29.26%)	11 (12.5%)
	Intersected	18 (21.95%)	43 (48.86%)
	Reticular	10 (12.19%)	9 (10.22%)
	Undetermined	6 (7.31%)	4 (4.54%)
	Poor Quality	13 (15.85%)	3 (3.40%)
III	Vertical	9 (10.97%)	12 (13.63%)
	Branched	4 (4.87%)	38 (43.18%)
	Intersected	41 (50.0%)	27 (30.68%)
	Reticular	14 (17.07%)	8 (9.09%)
	Undetermined	9 (10.97%)	8 (9.09%)
	Poor Quality	12 (14.63%)	2 (2.27%)
IV	Vertical	6 (7.31%)	20 (22.72%)
	Branched	10 (12.19%)	31 (35.22%)
	Intersected	32 (39.02%)	17 (19.31%)
	Reticular	8 (9.75%)	13 (14.77%)
	Undetermined	12 (14.63%)	9 (10.22%)
	Poor Quality	9 (10.97%)	0 (0.00%)

As per table no1 when the overall pattern was evaluated among all the lip compartments of the study subjects, it was found that intersecting pattern was most common among both males and females having 34.75% and 30.96% respectively. However, the least common was the undetermined pattern seen in 9.45% males and 7.67% females. The intersecting pattern was found to be most common among upper and lower lips of both males and females. The analysis of lip print type in each compartment was done. Among males, it was found that intersected pattern was most common in compartments 1, 3 and 4 having 28.04, 50.0 and 39.02 %, respectively, while the least common pattern in lip compartments 1, 2, was Undetermined with 4.87% and 7.31% respectively while in 3<sup>rd</sup> compartment Branched patter was least common with 4.87% and in 4<sup>th</sup> compartment Vertical pattern was least common with 7.31%. On evaluation of the lip prints of the females, compartments 1, 2 exhibited intersected pattern predominantly having 25.0% and 48.86% respectively. However, in compartment 3 and 4, branched pattern was commonest with 43.18 and 35.22% respectively. Lip compartments 1 of the

females showed the reticular pattern as the least common having 2.27%, while compartment 2, 3 and 4 had poor quality lip prints least in number.

## Discussion

Crimes challenge the society in detection, diagnosis and identification of criminals. Establishing a person's identity can be a very difficult process. The most commonly used techniques like the fingerprint, DNA and Dental identification cannot always be used. Hence the search for various other means of personal identification continues. It is known that due to their special features, both lip grooves and palatal rugae can be used successfully in human identification [17, 18]. Lip prints are very useful in forensic investigation and personal identification. They are considered to be most important forms of transfer evidence, and are analogous to finger prints.

Among males, it was found that intersected pattern was most common in compartments 1, 3 and 4, while

the least common pattern in lip compartments 1, 2, was Undetermined. On evaluation of the lip prints of the females, compartments 1, 2 exhibited intersected pattern predominantly. However, in compartment 3 and 4, branched pattern was commonest. These results of our study do not coincide with that by Vahanwala and Parekh who showed the Y-pattern dominant in females in third and fourth quadrants and end-to-end pattern common among males in second quadrant [21].

A detailed study of each lip print showed that each print is unique. This supports the findings of the earlier studies regarding the uniqueness of lip prints [19-25]. Thus, lip prints can be effectively used for personal identification. Hence Lip prints can be used to verify the presence or absence of a person from the crime, provided there has been consumption of beverage, drinks, usage of cloth, tissue/ napkin etc. at the crime scene [6]. Smears can also be found in other places, such as glasses, cups, spoons or cigarette butts, therefore indicating some kind of relationship between a suspect and the crime scene [21]. At scene of crime Investigating officers look for finger prints at all possible places, presence or absence of finger prints is conclusive of the fact that the person suspected was either present or absent on the scene of crime, likewise the lip print being uniform throughout the life and individualistic can be used to verify the presence or absence of a person from the scene of crime. Lip marks can be observed on ordinary drinking glass by an individual, even without lipstick being applied. Hence taking lip prints of all the suspected individuals and comparing with any such item found at the scene of crime could give conclusive evidence. Presence/ absence of a person and should be admissible even in the court of law. The other investigations become easier, once the presence/absence of a suspect from the scene are confirmed. In an investigation, Dr. Anil Aggarwal [26] has proved beyond doubt that lip prints are as good as finger prints in criminal identification and can be definitely used when no other means of traditional methods of identification are available.

#### *Heredity and Lip Print*

In our study we had a pair of twin, uniovular type were studied in details in all 04 quadrants. It was similar to in few quadrants, but one or the other give different pattern, it was consistent with the study of Mc donell who reported that two identical twins seemed to be indistinguishable by every other means but their lip prints were not identical. This was different from study by Tsuchihashi et al [20] in

which they found similar lip prints in twins and their parents. Though the size of samples for twin in our study was small but even one case of uniovular twins showing different pattern creates doubts for heredity in lip print identification.

#### **Conclusion**

When individual identification is concerned, Lip prints can be used as an aid, where other commonly used identification sources are not available. Lip prints are useful in personal identification and they differ from person to person even not similar in uniovular twins. Study showed that cellophane tape and lipstick can be easily used to retrieve lip prints. Lip print analysis is a process that can provide both qualitative and quantitative results; however, more research should be done to make its application widely accepted in the forensic field. Research suggests the conclusive evidence that lip prints are suitable for the successful comparison, analysis, and identification of a person to a crime. In fact, there have been convictions of perpetrators who were positively identified via the analysis of their known lip prints to those found at the crime scene. There is a need to develop one cohesive Cheiloscopy system. If police keep record of lip print with them along with fingerprint, it will help to solve the crime and can justify the real sinner. However, as far as the legal matters in Indian judicial system are concerned, this technique needs to be used more frequently in routine civil and criminal litigations.

#### **Acknowledgements**

Many thanks to the Principals of Government Schools located in village Narketpally, District Nalgonda, state Telangana for allowing data collection. Thanks are also due to the subjects who have voluntarily contributed to the study.

#### *Source of Funding*

Nil

#### *Conflicts of Interest*

Nil.

#### *Author Disclosures*

Authors have no conflict of interest. This study was a part of departmental research activities of

Forensic Medicine at Kamineni Institute of Medical Sciences, Narketpally.

## References

- Rastogi P, Parida A. Lip prints—An aid in Identification. *Aust J Forensic Sci.* 2011; 44: 1-8.
- Amith HV, Ankola AV, Nagesh L. Lip prints - Can it aid in individual identification. *J Oral Health Community Dent* 2011; 5: 113-8.
- Nishat A Sheikh et al. Cheiloscopy: A Tool for Solving Crime and Identification. *Indian Journal of Forensic Medicine and Toxicology.* July-Dec., 2012; 6(2): 133 -135.
- Romm S. On the beauty of lips. *Clin Plast Surg.* 1984; 11: 571-81.
- Ball J. The current status of lip prints and their use for identification. *J Forensic Odontostomatol.* 2002; 20: 43-6.
- Sharma P, Saxena S, Rathod V. Comparative reliability of Cheiloscopy and palatoscopy in human identification. *Indian J Dent Res.* 2009; 20: 453-7.
- Cottene JA, Standish SM. *Text Book of Outline of Forensic Dentistry; Special Tech (Cheiloscopy).* 1st ed, Chicago. 1982; pp. 77-111.
- Sharma P, Saxena S, Rathod V. Cheiloscopy: The study of lip prints in sex identification. *Forensic Dent Sci.* 2009; 1: 24-7.
- Rajendran R, Sivapathasundharam B. *Shafer's Textbook of Oral Pathology.* 6th ed. New Delhi: Elsevier. 2006; pp. 896-7.
- Nishat Ahmed Sheikh et al. A study of Finger Prints in Relation to ABO Blood Group and Gender. *Indian Journal of Forensic Medicine and Pathology.* October - December 2014; 7(4): 141-146.
- Dwivedi N, Agarwal A, Kashyap B, Raj V, Chandra S. Latent lip print development and its role in suspect Identification. *J Forensic Dent Sci.* 2013; 5: 22-7.
- Kasprzak J. Possibilities of Cheiloscopy. *Forensic Sci Int.* 1990; 46: 145-51.
- Snyder LM. *Homicide Investigation,* 2nd ed. Springfield: Charles C. Thomas. 1967; pp. 65.
- Snyder LM. *Textbook of homicide investigation. Identification of dead bodies.* 1950.
- Suzuki K, Tsuchihashi Y. Personal identification by means of lip prints. *J Forensic Med* 1970; 17: 52-7.
- Saraswathi TR, Mishra G, Ranganathan K. Study of lip prints. *J Forensic Dent Sci.* 2009; 1: 28-31.
- Caldas IM, Magalhaes T, Afonso A. Establishing identity using Cheiloscopy and palatoscopy. *Forensic Sci Int;* accepted 21 April 2006. Article in Press. Available from URL: <http://www.science-direct.com/sdarticle.pdf>.
- Limson KS, Julian R. Computerized recording of the palatal rugae pattern and an evaluation of its application in forensic identification. *J Forensic Odontostomatol* 2004; 22(1): 1-4.
- Sivapathasundharam B, Prakash PA, Sivakumar G. Lip prints (Cheiloscopy). *Ind J Dent Res.* 2001; 12(4): 234-237.
- Tsuchihashi Y. Studies on personal identification by means of lip prints. *Forensic Sci.* 1974; 3: 233-248.
- Vahanwala SP, Parekh BK. Study of lip prints as an aid to forensic methodology. *J Forensic Med Toxicol.* 2000; 17(1): 12-17.
- Suzuki K, Tsuchihashi Y. A new attempt of personal identification by means of lip print. *Can Soc Forensic Sci.* 1971; 4: 154-158.
- Jaishankar S, Jaishankar N, Shanmugam S. Lip prints in personal identification. *J Indian Acad Dent Specialists.* 2010; 1(4): 23-26.
- Singh S, Chhikara P, Singroha R. Lip Prints as evidence. *J Punjab Acad Forensic Med Toxicol.* 2011; 11(1): 23-25.
- Lip prints identification anyone? Available online at [http://www.forensic-evidence.com/sie/ID/ID00004\\_10.html](http://www.forensic-evidence.com/sie/ID/ID00004_10.html).
- Aggarwal A. The importance of lip prints (Forensic Files). Available from: <http://lifeloom.com/II2Aggarwal.htm>. 24th Oct 2008.